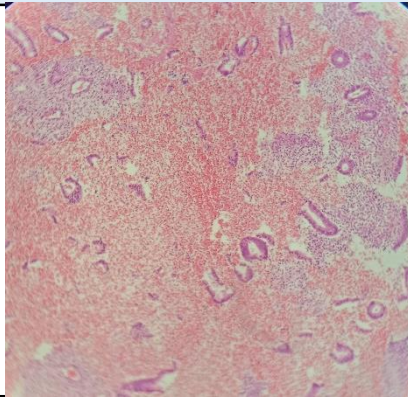


Patient Name	Mrs. KAVITA 36673	Client Name	Pushpanjali Hospital	Specimen Received	16/08/19
Age/Sex	30 Years/Female	(Rewari)		Specimen Type	Tissue
Patient ID	011908160269			Collection Date	16/08/19
Specimen ID	MOLQ/B-1555/19			Report Date	20/08/19

SURGICAL PATHOLOGY REPORT Endometrium

DIAGNOSIS

PROLIFERATIVE PHASE



SPECIMEN

Endometrium

GROSS

Received multiple grayish white tissue piece.

Microscopy

Section examined shows small endometrial glands with cuboidal lining with small round nucleus. Stroma shows mononuclear inflammatory cells. No granuloma seen. No malignant cells seen.

Note : All biopsy specimen will be stored for 15 (fifteen) days, block and slides for 5 (five) years only from the time of receipt at the laboratory. No request, for any of the above, will be entertained after the due date.

Reference

- i) Rosai and Ackerman's Surgical Pathology.
- ii) Modern Surgical Pathology.

A handwritten signature in black ink, appearing to read 'Gulshan'.

Gulshan Yadav, MD
Consultant Pathologist