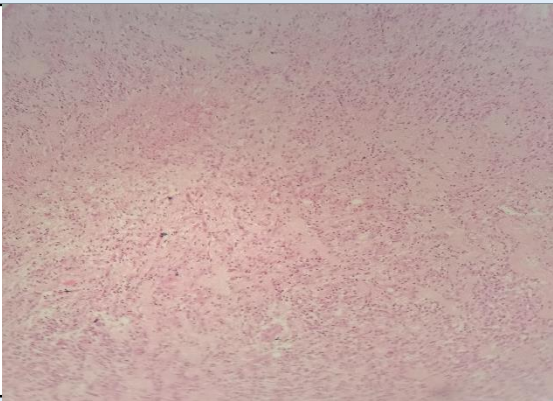


| | | | | | |
|---------------------|----------------------------|--------------------|-------------------------|--------------------------|----------|
| Patient Name | Master. MOHAN SINGH | Client Name | Galaxy Hospital, Palwal | Specimen Received | 12/08/19 |
| Age/Sex | 08 Years/Male | | | Specimen Type | Tissue |
| Patient ID | 011908120214 | | | Collection Date | 12/08/19 |
| Specimen ID | MOLQ/B-1549/19 | | | Report Date | 20/08/19 |

SURGICAL PATHOLOGY REPORT
Mandibular Lymph Nodes

DIAGNOSIS

INFECTIVE LESION



SPECIMEN
Mandibular Lymph Nodes

GROSS
Received 4 grayish white tissue piece measuring 1x1 cm each.

Microscopy

1. Section examined shows multiple bits of tissue with fibrocollagenous tissue and inflammatory cells chiefly composed of polymorphs and lymphocytes.
2. Presence of normal muscle bundles and few mature adipose cells.
3. No evidence of lymphoid follicles observed.
4. No granuloma seen. No malignant cells seen.

Note : All biopsy specimen will be stored for 15 (fifteen)days, block and slides for 5(five) years only from the time of receipt at the laboratory. No request ,for any of the above ,will be entertained after the due date.

Reference

- i) Rosai and Ackerman's Surgical Pathology.
- ii) Modern Surgical Pathology.

Tina Bhardwaj, MDS
Consultant Oral Histopathologist

Gulshan Yadav, MD
Consultant Pathologist