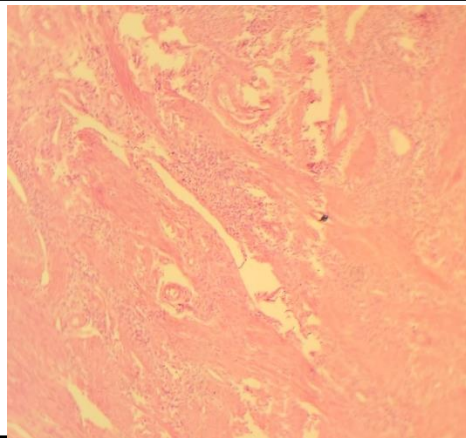


Patient Name	Mrs. MAYA 30054	Client Name	Pushpanjali Hospital (Rewari)	Specimen Received	12-Jul-2019
Age/Sex	45 Years/Female			Specimen Type	Tissue
Patient ID	011908120245			Collection Date	12-Jul-2019
Specimen ID	MOLQ/B-1548/19			Report Date	16-Jul-2019 9

SURGICAL PATHOLOGY REPORT

Uterus with Cervix

CHRONIC CERVICITIS WITH ENDOCERVICAL POLYP



SPECIMEN

Uterus with Cervix

GROSS

Received 9x4 cm uterus with cervix. Cut section shows multiple fibroids measuring 1x1 cm and 1x1 cms. Cervix shows poly measuring 1x1 cm.

Microscopy

Section examined shows

- 1) Endometrium with proliferative phase
- 2) Myometrium with muscle bundles
- 3) Cervix with mononuclear inflammatory cells
- 4) Polyp with endocervical glands with cuboidal lining epithelium with round nucleus suggestive of endocervical polyp

Note : All biopsy specimen will be stored for 15 (fifteen) days, block and slides for 5 (five) years only from the time of receipt at the laboratory. No request for any of the above, will be entertained after the due date.

Reference

- i) Rosai and Ackerman's Surgical Pathology.
- ii) Modern Surgical Pathology.

Gulshan Yadav, MD
Consultant Pathologist