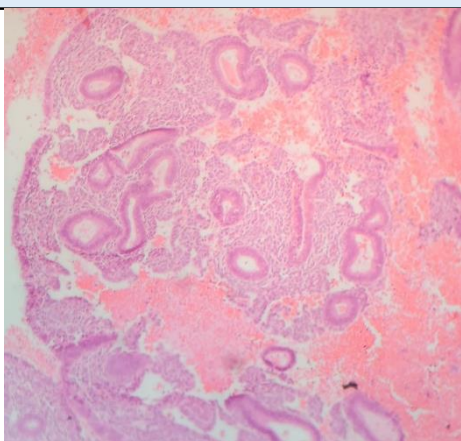


Patient Name	Mrs. PARVEEN	Client Name	SBS Diagnostic Centre,	Specimen Received	11-Jul-2019
Age/Sex	46 Years/Female		Gurgaon	Specimen Type	Tissue
Patient ID	011908110200			Collection Date	11-Jul-2019
Specimen ID	MOLQ/B-1546/19			Report Date	16-Jul-2019 9

SURGICAL PATHOLOGY REPORT

Endometrium

DISORDERED PROLIFERATIVE PHASE



SPECIMEN

Endometrium

GROSS

Received multiple greyish white tissue piece.

Microscopy

1. Section examined shows small and tortuous endometrial glands with cuboidal lining with small round nucleus. Stroma shows mononuclear inflammatory cells.
2. No granuloma seen. No malignant cells seen.

Note : All biopsy specimen will be stored for 15 (fifteen) days, block and slides for 5 (five) years only from the time of receipt at the laboratory. No request for any of the above, will be entertained after the due date.

Reference

- i) Rosai and Ackerman's Surgical Pathology.
- ii) Modern Surgical Pathology.

A handwritten signature in black ink, appearing to read 'Gulshan', written over a light blue rectangular background.

Gulshan Yadav, MD
Consultant Pathologist