

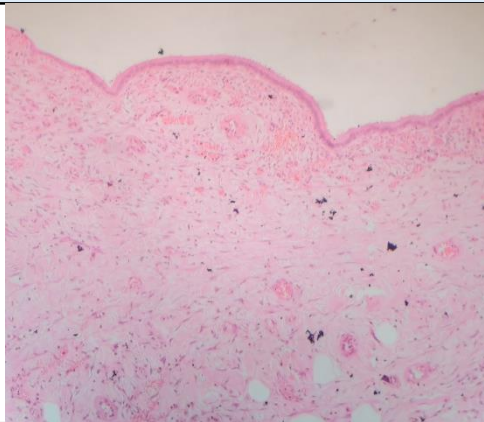
Patient Name	Mrs. IMRETI	Client Name	Care Diagnostics Centre, Gurgaon	Specimen Received	11-Aug-2019
Age/Sex	85 Years/Female			Specimen Type	Tissue
Patient ID	011908110163			Collection Date	11-Aug-2019
Specimen ID	MOLQ/B-1545/19			Report Date	16-Aug-2019

SURGICAL PATHOLOGY REPORT

GALL BLADDER.

DIAGNOSIS

CHOLECYSTITIS AND CHOLELITHIASIS.



SPECIMEN

Gall Bladder.

GROSS

Received 10x3.8cm long gall bladder already cut open with stones. Wall thickness 0.3 mm.

Microscopy

- Section examined shows ulcerative mucosa with mild anisonucleosis and Rokitansky Aschoff sinuses (irregularly shaped tubular structures lined by cuboidal lining epithelium with round to oval nucleus) with fibro collagenous tissue and inflammatory cells (lymphocytes).

Note : All biopsy specimen will be stored for 15 (fifteen) days, block and slides for 5 (five) years only from the time of receipt at the laboratory. No request ,for any of the above will be entertained after the due date.

Reference

- Rosai and Ackerman's Surgical Pathology.
- Modern Surgical Pathology.

Gulshan Yadav, MD
Consultant Pathologist