

Patient Name Mr. PRADEEP
Age/Sex 38 Years/Male
Patient ID 011908110057
Specimen ID MOLQ/B-1544/19

Client Name Surya Path Lab,
Manesar

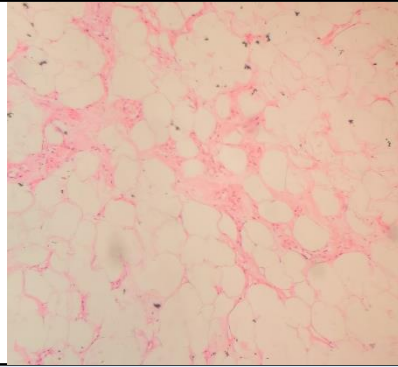
Specimen Received 11-Aug-2019
Specimen Type Tissue
Collection Date 11-Aug-2019
Report Date 16-Aug-2019

SURGICAL PATHOLOGY REPORT

LIPOMA

DIAGNOSIS

LIPOMA



SPECIMEN LIPOMA

GROSS

Received 3.7x3 cm yellowish tissue piece.


Microscopy

1. Section examined shows mature adipose cells with few inflammatory cells and few areas reveal fibrocollagenous tissue.
2. No granuloma seen. No malignant cells seen.

Note : All biopsy specimen will be stored for 15 (fifteen)days, block and slides for 5(five) years only from the time of receipt at the laboratory. No request ,for any of the above ,will be entertained after the due date.

Reference

- i) Rosai and Ackerman's Surgical Pathology.
- ii) Modern Surgical Pathology.



Gulshan Yadav, MD
Consultant Pathologist