

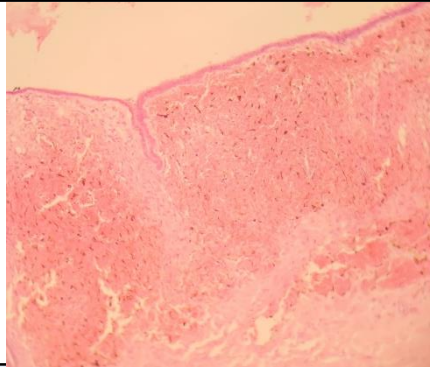
Patient Name	Baby. JASHITA 36132	Specimen Received	10-Aug-2019
Age/Sex	12 Years/Female	Specimen Type	Tissue
Patient ID	011908100316	Collection Date	10-Aug-2019
Specimen ID	MOLQ/B-1542/19	Report Date	16-Aug-2019

SURGICAL PATHOLOGY REPORT

Paraovarian Cyst (Side not mentioned)

DIAGNOSIS

HEMORRHAGIC CYST



SPECIMEN

Paraovarian Cyst (Side not mentioned)

GROSS

Received 3.4x2.8 cm grayish white tissue piece.


Microscopy

1. Section examined shows lining epithelium with cuboidal cells having round nucleus with large number of RBCs.

Note : All biopsy specimen will be stored for 15 (fifteen)days, block and slides for 5(five) years only from the time of receipt at the laboratory. No request ,for any of the above ,will be entertained after the due date.

Reference

- i) Rosai and Ackerman's Surgical Pathology.
- ii) Modern Surgical Pathology.



Gulshan Yadav, MD
Consultant Pathologist