

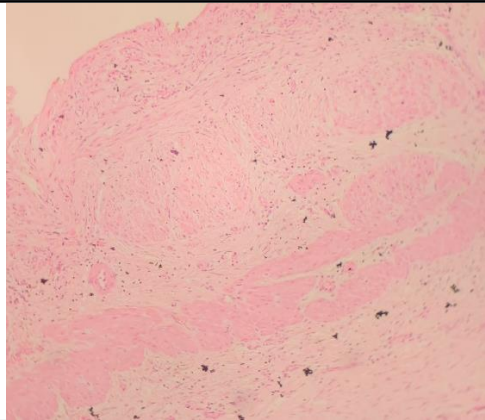
Patient Name	Ms. LALPARI DEVI	Specimen Received	10-Aug-2019
Age/Sex	35 Years/Female	Specimen Type	Tissue
Patient ID	011908100302	Client Name	Umkal Hospital.
Specimen ID	MOLQ/B-1540/19	Collection Date	10-Aug-2019
		Report Date	16-Aug-2019

SURGICAL PATHOLOGY REPORT

GALL BLADDER.

DIAGNOSIS

CHOLECYSTITIS AND CHOLELITHIASIS.



SPECIMEN

Gall Bladder.

GROSS

Received 7.1x4.8cm long gall bladder. Cut section shows tiny stones.

Microscopy

- Section examined shows ulcerative mucosa with mild anisonucleosis and rokitansky aschoff sinus (irregularly shaped tubular structures lined by cuboidal lining epithelium with round to oval nucleus) with fibro collagenous tissue and inflammatory cells (lymphocytes).

Note : All biopsy specimen will be stored for 15 (fifteen) days, block and slides for 5 (five) years only from the time of receipt at the laboratory. No request ,for any of the above will be entertained after the due date.

Reference

- Rosai and Ackerman's Surgical Pathology.
- Modern Surgical Pathology.

**Gulshan Yadav, MD
Consultant Pathologist**