

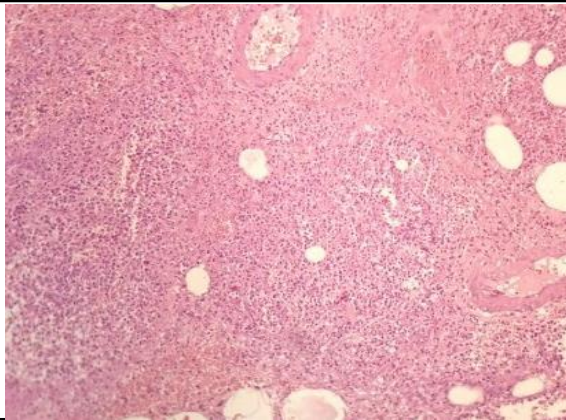
Patient Name	Mr. RAJEEV KUMAR	Client Name	Umkal Hospital	Specimen Received	10/08/19
Age/Sex	22 Years/Male			Specimen Type	Tissue
Patient ID	011908100068			Collection Date	10/08/19
Specimen ID	MOLQ/B-1532/19			Report Date	14/08/19

SURGICAL PATHOLOGY REPORT

Appendix

DIAGNOSIS

Acute on chronic appendicitis.



SPECIMEN

Appendix

GROSS

Received 3.8x1cm long appendix. Cut section shows feco-lith.

Microscopy

Section examined shows lymphoid follicles with ulcerative mucosa. Deeper tissue shows inflammatory cells (polymorphs and lymphocytes, eosinophil). No granuloma seen. No malignant cells seen.

Note : All biopsy specimen will be stored for 15 (fifteen)days, block and slides for 5(five) years only from the time of receipt at the laboratory. No request ,for any of the above ,will be entertained after the due date.

Reference

- i) Rosai and Ackerman's Surgical Pathology.
- ii) Modern Surgical Pathology.

Gulshan Yadav, MD
Consultant Pathologist