

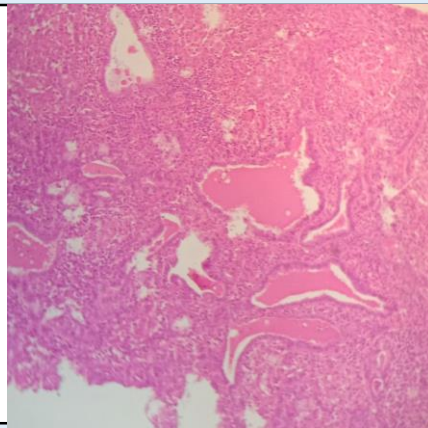
<b>Patient Name</b>	<b>Mrs. POOJA</b>	<b>Client Name</b>	Lalita Memorial Hospital	<b>Specimen Received</b>	09/08/19
<b>Age/Sex</b>	40 Years/Female		Pvt. Ltd. (Rewari)	<b>Specimen Type</b>	Tissue
<b>Patient ID</b>	011908090311			<b>Collection Date</b>	09/08/19
<b>Specimen ID</b>	MOLQ/B-1528/19			<b>Report Date</b>	14/08/19

## SURGICAL PATHOLOGY REPORT

Uterus with tube and ovary..

### DIAGNOSIS

**CHRONIC CERVICITIS WITH GRANULOMATOUS REACTION IN TUBE.**



#### SPECIMEN

Uterus with tube and ovary.

#### GROSS

Received 9x5.8 cm uterus with cervix with bilateral adnexa. Ovary size 4x4 cm, 4x4 cm ovary cut section shows cheese material with Paratubal cyst .

#### Microscopy

Section examined shows

- 1)Endometrium with proliferative phase
- 2)Myometrium with muscle bundles
- 3)Cervix with nabothelial cyst, squamous lining epithelium, mononuclear inflammatory cells.
- 4)Ovary with simple cyst. Tube shows granulomatous reaction with MNGC suggestive of granulomatous reaction.
- 5)Other ovary and tube unremarkable

**Note :** All biopsy specimen will be stored for 15 (fifteen)days, block and slides for 5(five) years only from the time of receipt at the laboratory. No request ,for any of the above ,will be entertained after the due date.

#### Reference

- i) Rosai and Ackerman's Surgical Pathology.
- ii) Modern Surgical Pathology.

**Gulshan Yadav, MD**  
Consultant Pathologist