

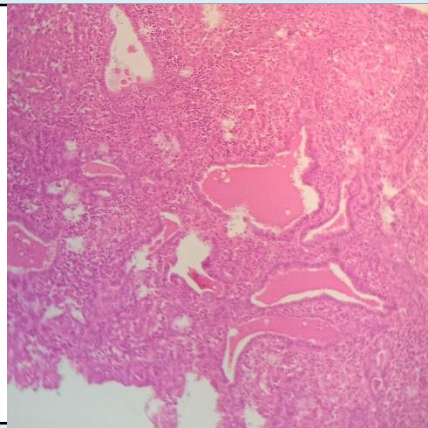
Patient Name	Mrs. POOJA	Client Name	Lalita Memorial Hospital	Specimen Received	09/08/19
Age/Sex	40 Years/Female		Pvt. Ltd. (Rewari)	Specimen Type	Tissue
Patient ID	011908090311			Collection Date	09/08/19
Specimen ID	MOLQ/B-1528/19			Report Date	14/08/19

SURGICAL PATHOLOGY REPORT

Uterus with tube and ovary

DIAGNOSIS

CHRONIC CERVICITIS WITH GRANULOMATOUS REACTION IN TUBES.



SPECIMEN

Uterus with tube and ovary.

GROSS

Received 9x5.8 cm uterus with cervix with bilateral adnexa. Ovary size 4x4 cm, 4x4 cm ovary cut section shows cheese material with Paratubal cyst .

Microscopy

Section examined shows

- 1)Endometrium with proliferative phase
- 2)Myometrium with muscle bundles
- 3)Cervix with nabothial cyst, squamous lining epithelium, mononuclear inflammatory cells.
- 4)Ovary with simple cyst. Tube shows granulomatous reaction with multinucleated giant cells suggestive of granulomatous reaction.
- 5)Other ovary with simple cyst. Tube shows granulomatous reaction with multinucleated giant cells suggestive of granulomatous reaction.

Note : All biopsy specimen will be stored for 15 (fifteen)days, block and slides for 5(five) years only from the time of receipt at the laboratory. No request ,for any of the above ,will be entertained after the due date.

Reference

- i) Rosai and Ackerman's Surgical Pathology.
- ii) Modern Surgical Pathology.

**Gulshan Yadav, MD
Consultant Pathologist**