

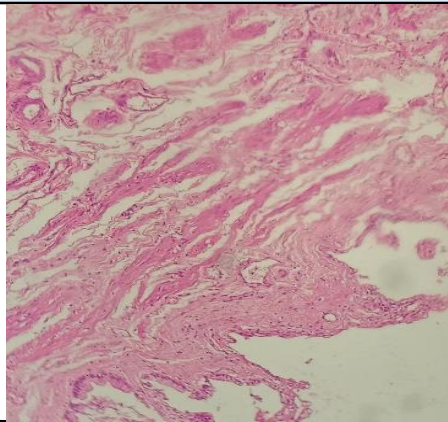
Patient Name	Mrs. SHUKHIRA BIBI	Client Name	Lifeaid Wellness Centre	Specimen Received	09/08/19
Age/Sex	28 Years/Female			Specimen Type	Tissue
Patient ID	011908090282			Collection Date	09/08/19
Specimen ID	MOLQ/B-1531/19			Report Date	14/08/19

SURGICAL PATHOLOGY REPORT

Gall Bladder

DIAGNOSIS

CHOLECYSTITIS AND CHOLELITHIASIS.



SPECIMEN

Gall Bladder

GROSS

Received 6x2.1cm long gall bladder. Cut section shows stones wall thickness 0.3cm.

Microscopy

Section examined shows ulcerative mucosa and Rokitansky-Aschoff sinuses (irregularly shaped tubular structures lined by cuboidal lining epithelium with round to oval nucleus) with fibrocollagenous tissue and inflammatory cells (lymphocytes).

Note : All biopsy specimen will be stored for 15 (fifteen) days, block and slides for 5 (five) years only from the time of receipt at the laboratory. No request, for any of the above, will be entertained after the due date.

Reference

- i) Rosai and Ackerman's Surgical Pathology.
- ii) Modern Surgical Pathology.

Gulshan Yadav, MD
Consultant Pathologist