

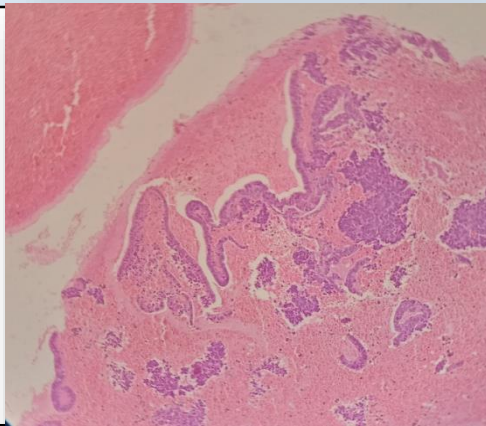
Patient Name	NIKITA	Client Name	Expert Healthcare Centre	Specimen Received	09/08/19
Age/Sex	21 YRS/F			Specimen Type	Tissue
Patient ID	011908090066			Collection Date	09/08/19
Specimen ID	MOLQ/B-1526/19			Report Date	14/08/19

SURGICAL PATHOLOGY REPORT

Endometrium

DIAGNOSIS

Disordered proliferative phase



SPECIMEN

Endometrium

GROSS

Received multiple grayish white tissue piece.

Microscopy

Section examined shows small endometrial glands with columnar lining epithelium with round to oval nucleus stroma shows mononuclear inflammatory cells and RBCs and few cells shows squamous metaplasia. No granuloma seen. No malignant cells seen.

Note : All biopsy specimen will be stored for 15 (fifteen)days, block and slides for 5(five) years only from the time of receipt at the laboratory. No request ,for any of the above ,will be entertained after the due date.

Reference

- i) Rosai and Ackerman's Surgical Pathology.
- ii) Modern Surgical Pathology.

Gulshan Yadav, MD
Consultant Pathologist