

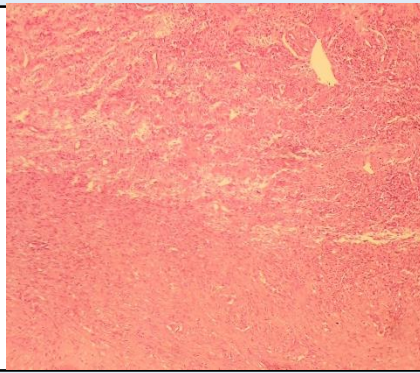
<b>Patient Name</b>	<b>Ms. HARSHA</b>	<b>Client Name</b>	Shri Balaji Multispeciality Hospital, Gurgaon	<b>Specimen Received</b>	02-Aug-2019
<b>Age/Sex</b>	28 Years/Female			<b>Specimen Type</b>	Tissue
<b>Patient ID</b>	011908020135			<b>Collection Date</b>	02-Aug-2019
<b>Specimen ID</b>	MOLQ/B-1481-19			<b>Report Date</b>	14-Aug-2019

## SURGICAL PATHOLOGY REPORT

### Ovarian Cyst (Side not mentioned)

#### DIAGNOSIS

### SUSPICIOUS OF ENDOMETRIOMA



#### **SPECIMEN**

Ovarian Cyst (Side not mentioned)

#### **GROSS**

Received 3x4 cm greyish white tissue piece already cut open.

#### **Microscopy**

1. Section examined shows ovarian tissue with columnar lining epithelium.
2. Section also shows hemosiderin laden macrophages.
3. No malignant cells seen.

**Note :** All biopsy specimen will be stored for 15 (fifteen)days, block and slides for 5(five) years only from the time of receipt at the laboratory. No request ,for any of the above ,will be entertained after the due date.

#### **Reference**

- i) Rosai and Ackerman's Surgical Pathology.
- ii) Modern Surgical Pathology.

**Gulshan Yadav, MD**  
Consultant Pathologist