

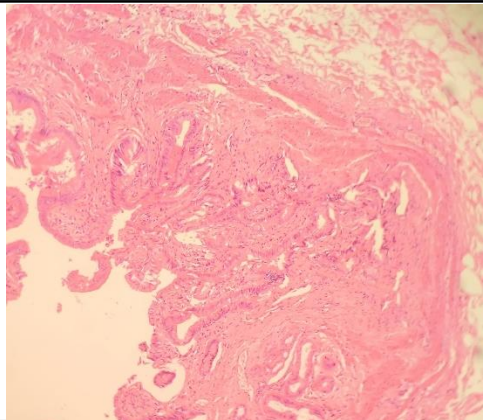
Patient Name	Mrs. MEENA	Client Name	Civil Hospital Sec-10, Gurgaon	Specimen Received	07-Aug-2019
Age/Sex	24 Years/Female			Specimen Type	Tissue
Patient ID	011908070368			Collection Date	07-Aug-2019
Specimen ID	MOLQ/B-1516/19			Report Date	11-Aug-2019

SURGICAL PATHOLOGY REPORT

GALL BLADDER.

DIAGNOSIS

CHOLECYSTITIS AND CHOLELITHIASIS.



SPECIMEN

Gall Bladder.

GROSS

Received 5.9x2.8 long gall bladder. Cut section shows tiny stones.

Microscopy

- Section examined shows ulcerative mucosa and Rokitansky-Aschoff sinuses (irregularly shaped tubular structures lined by cuboidal lining epithelium with round to oval nucleus) with fibrocollagenous tissue and inflammatory cells (lymphocytes).

Note : All biopsy specimen will be stored for 15 (fifteen) days, block and slides for 5 (five) years only from the time of receipt at the laboratory. No request for any of the above will be entertained after the due date.

Reference

- Rosai and Ackerman's Surgical Pathology.
- Modern Surgical Pathology.

Gulshan Yadav, MD
Consultant Pathologist