

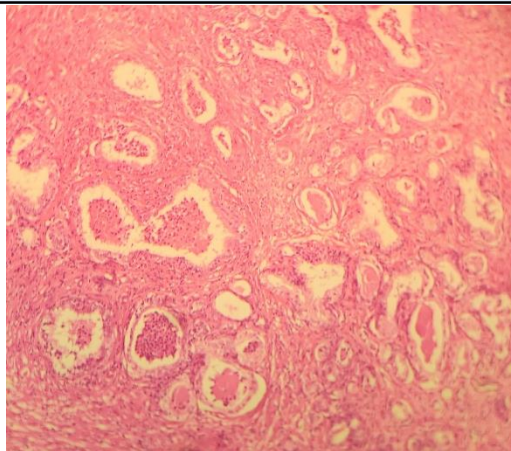
Patient Name	Mr. RATI RAM 35947	Client Name	Pushpanjali Hospital,	Specimen Received	02-Aug-2019
Age/Sex	78 Years/Male		Rewari	Specimen Type	Tissue
Patient ID	011908060278			Collection Date	02-Aug-2019
Specimen ID	MOLQ/B-1504/19			Report Date	11-Aug-2019

SURGICAL PATHOLOGY REPORT

TURP Chips

DIAGNOSIS

BENIGN PROSTATIC HYPERPLASIA



SPECIMEN
TURP Chips

GROSS

Received multiple grayish white tissue piece, 5x5 cm in aggregate. Weight 14.0 grams.

Microscopy

1. Section examined shows bilayered prostatic glands with columnar lining epithelium and with small round to oval nucleus surrounded by large number of fibrocollagenous tissue and mononuclear inflammatory cell.
2. No granuloma seen. No malignant cells seen.

Note : All biopsy specimen will be stored for 15 (fifteen)days, block and slides for 5(five) years only from the time of receipt at the laboratory. No request ,for any of the above ,will be entertained after the due date.

Reference

- i) Rosai and Ackerman's Surgical Pathology.
- ii) Modern Surgical Pathology.

Gulshan Yadav, MD
Consultant Pathologist