

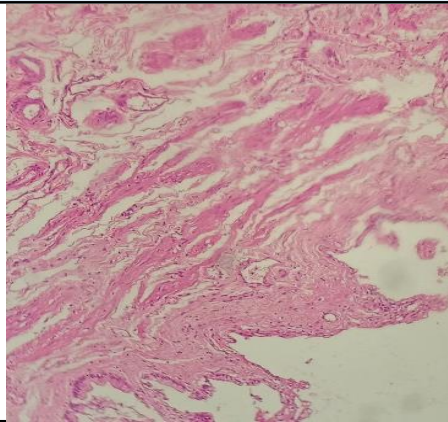
<b>Patient Name</b>	MALTI DEVI	<b>Client Name</b>	Accurate Path (C), Agra	<b>Specimen Received</b>	06/08/19
<b>Age/Sex</b>	23 YRS/F			<b>Specimen Type</b>	Tissue
<b>Patient ID</b>	011908060007			<b>Collection Date</b>	06/08/19
<b>Specimen ID</b>	MOLQ/B-1503/19			<b>Report Date</b>	09/08/19

## SURGICAL PATHOLOGY REPORT

### Gall Bladder

#### DIAGNOSIS

**CHOLECYSTITIS AND CHOLELITHIASIS.**



**SPECIMEN**  
Gall Bladder

**GROSS**

Received 7x2.8cm long gall bladder already cut open with stones.


**Microscopy**

Section examined shows ulcerative mucosa and Rokitansky-Aschoff sinuses (irregularly shaped tubular structures lined by cuboidal lining epithelium with round to oval nucleus) with fibro collagenous tissue and inflammatory cells (lymphocytes).

**Note :** All biopsy specimen will be stored for 15 (fifteen) days, block and slides for 5 (five) years only from the time of receipt at the laboratory. No request, for any of the above, will be entertained after the due date.

**Reference**

- i) Rosai and Ackerman's Surgical Pathology.
- ii) Modern Surgical Pathology.

  
**Gulshan Yadav, MD**  
**Consultant Pathologist**