

Patient Name	Mrs. PUSHPA PANDE	Client Name	SBS Diagnostic Centre, Gurgaon	Specimen Received	31-Jul-2019
Age/Sex	63 Years/Female			Specimen Type	Tissue
Patient ID	011907310080			Collection Date	31-Jul-2019
Specimen ID	MOLQ/B-1472-19			Report Date	05-Aug-2019

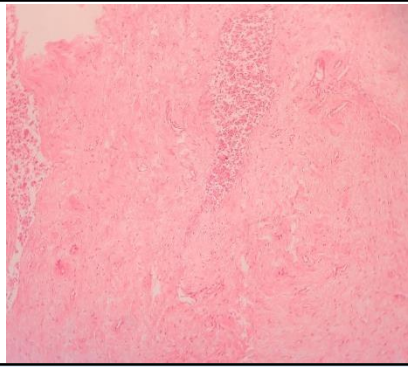
SURGICAL PATHOLOGY REPORT

Container 1: Uterus with Right Ovary

Container 2: Left Ovary

DIAGNOSIS

CHRONIC CERVICITIS WITH ENDOMETRIAL POLYP IMPRESSION



SPECIMEN

Container 1: Uterus with
Right Ovary
Container 2: Left Ovary

GROSS

Container 1 (Uterus with Right Ovary): Received 8.1x4.2 cm uterus with cervix with unilateral ovary and tube. Ovary size 2.5x1.5 cms. Cut section of uterus shows 2.5x1.5 cm polyp.
Container 2 (Left Ovary): Received 3.1x1.8 cm ovary and tube.

Microscopy

Container 1 (Uterus with Right Ovary): Section examined shows

- 1) Polyp with endometrial glands and stroma with mononuclear cells.
- 2) Endometrium with proliferative phase
- 3) Myometrium with adenomyosis
- 4) Cervix with mononuclear inflammatory cells
- 5) Right Ovary with Luteal Cyst and tube unremarkable

Container 2 (Left Ovary): Section examined shows

- 1) Left Ovary with Luteal Cyst and tube unremarkable

Note : All biopsy specimen will be stored for 15 (fifteen) days, block and slides for 5 (five) years only from the time of receipt at the laboratory. No request, for any of the above, will be entertained after the due date.

Reference

- i) Rosai and Ackerman's Surgical Pathology.
- ii) Modern Surgical Pathology. Report generated at MolQ Laboratory, Gurgaon

Gulshan Yadav, MD
Consultant Pathologist