

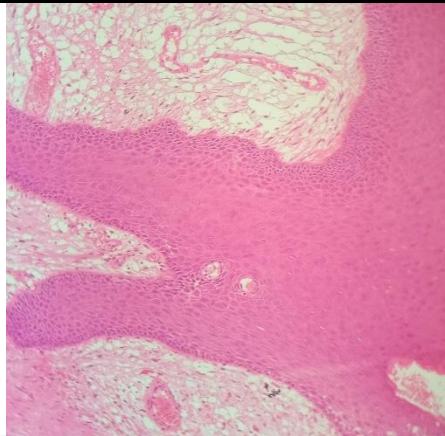
<b>Patient Name</b>	DEEN MOHD SHAH/NAMBAL	<b>Client Name</b>	Patients Care Clinical	<b>Specimen Received</b>	04/08/2019
<b>Age/Sex</b>	40 YRS/M		Laboratory, Jammu & Kashmir	<b>Specimen Type</b>	Tissue
<b>Patient ID</b>	011908040380			<b>Collection Date</b>	04/08/2019
<b>Specimen ID</b>	MOLQ/B-1497/19			<b>Report Date</b>	08/08/2019

## SURGICAL PATHOLOGY REPORT

Vocal cord nodule.

### DIAGNOSIS

**Vocal nodule with inflammation.**



#### SPECIMEN

Vocal cord nodule.

#### GROSS

Received 1x1cm grayish white tissue piece.

#### Microscopy

Section examined shows squamous lining epithelium with round to oval nucleus. deeper tissue shows fibro collagenous tissue, blood vessels and Hemorrhagic area and hemosiderin laden macrophages and inflammatory cells with mild atypia.

**Note :** All biopsy specimen will be stored for 15 (fifteen)days, block and slides for 5(five) years only from the time of receipt at the laboratory. No request ,for any of the above ,will be entertained after the due date.

#### Reference

- i) Rosai and Ackerman's Surgical Pathology.
- ii) Modern Surgical Pathology.

**Gulshan Yadav, MD**  
Consultant Pathologist