

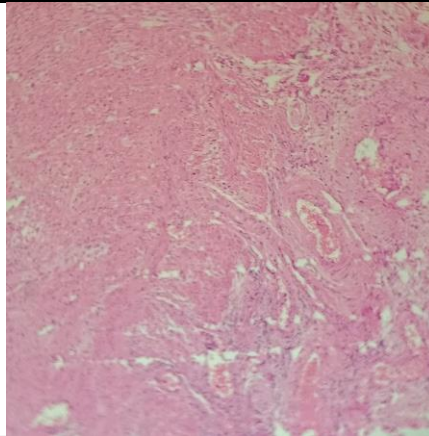
Patient Name	SHAHZADA/QAIMOH	Client Name	Patients Care Clinical	Specimen Received	04/08/2019
Age/Sex	45 YRS/F		Laboratory, Jammu & Kashmir	Specimen Type	Tissue
Patient ID	011908040379			Collection Date	04/08/2019
Specimen ID	MOLQ/B-1498/19			Report Date	08/08/2019

SURGICAL PATHOLOGY REPORT

Gall Bladder

DIAGNOSIS

CHOLECYSTITIS AND CHOLELITHIASIS.



SPECIMEN
Gall Bladder

GROSS

Received 6.8x2.1cm long gall bladder. Cut section shows stones.

Microscopy

Section examined shows ulcerative mucosa and Rokitansky Aschoff sinuses (irregularly shaped tubular structures lined by cuboidal lining epithelium with round to oval nucleus) with fibrocollagenous tissue and inflammatory cells (lymphocytes).

Note : All biopsy specimen will be stored for 15 (fifteen) days, block and slides for 5 (five) years only from the time of receipt at the laboratory. No request, for any of the above, will be entertained after the due date.

Reference

- i) Rosai and Ackerman's Surgical Pathology.
- ii) Modern Surgical Pathology.

Gulshan Yadav, MD
Consultant Pathologist