

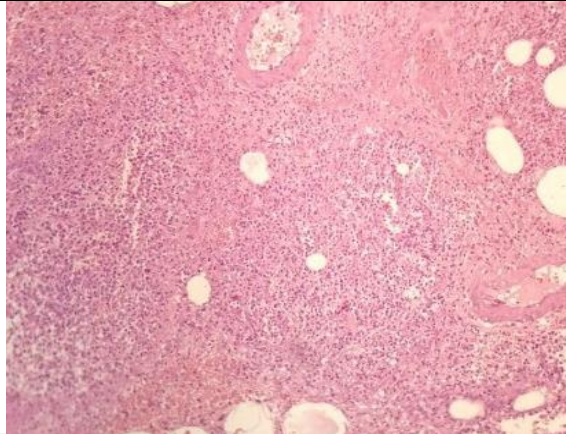
Patient Name	ANITA DEVI	Client Name	Lifeaid Wellness Centre	Specimen Received	04/08/2019
Age/Sex	31 YRS/F			Specimen Type	Tissue
Patient ID	011908040250			Collection Date	04/08/2019
Specimen ID	MOLQ/B-1495/19			Report Date	08/08/2019

SURGICAL PATHOLOGY REPORT

Appendix

DIAGNOSIS

ACUTE APPENDICITIS



SPECIMEN

Appendix

GROSS

Received 4.8x1.2cm long appendix. Cut section shows feco-lith.

Microscopy

Section examined shows lymphoid follicles with ulcerative mucosa. Deeper tissue shows inflammatory cells (polymorphs and lymphocytes). No granuloma seen. No malignant cells seen.

Note : All biopsy specimen will be stored for 15 (fifteen) days, block and slides for 5 (five) years only from the time of receipt at the laboratory. No request, for any of the above, will be entertained after the due date.

Reference

- i) Rosai and Ackerman's Surgical Pathology.
- ii) Modern Surgical Pathology.

Gulshan Yadav, MD
Consultant Pathologist