

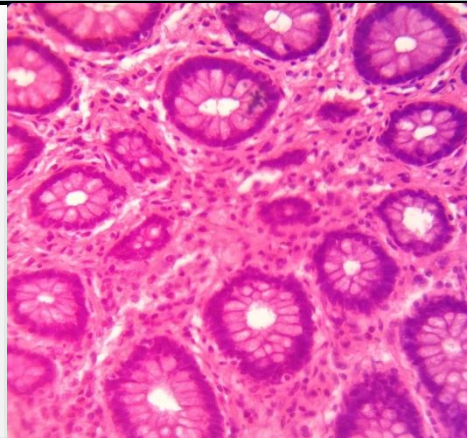
Patient Name	Mrs. KIRAN DEVI	Client Name	Civil Hospital Sec-10	Specimen Received	03/08/2019
Age/Sex	36 Years/Female			Specimen Type	Tissue
Patient ID	011908030229			Collection Date	03/08/2019
Specimen ID	MOLQ/B-1489/19			Report Date	08/08/2019

SURGICAL PATHOLOGY REPORT

Hemorrhoids

DIAGNOSIS

HEMORROIDS



SPECIMEN

Hemorrhoids.

GROSS

Received 1x1 cm greyish white tissue piece.

Microscopy

1. Section examined shows submucosal glands, fibro collagenous tissue with blood vessels.

No granuloma and no malignant cells seen.

Note : All biopsy specimen will be stored for 15 (fifteen)days, block and slides for 5(five) years only from the time of receipt at the laboratory. No request ,for any of the above ,will be entertained after the due date.

Reference

- i) Rosai and Ackerman's Surgical Pathology.
- ii) Modern Surgical Pathology.

Gulshan Yadav, MD
Consultant Pathologist