

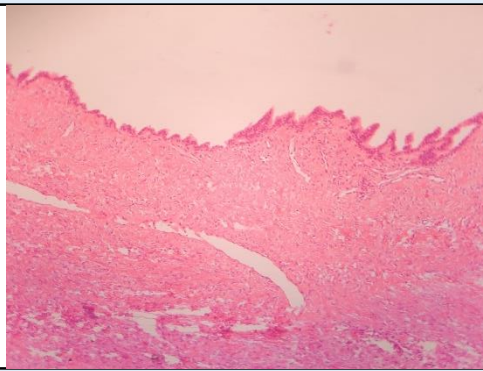
<b>Patient Name</b>	<b>Mrs. MARIYAM YADAV</b>	<b>Specimen Received</b>	02-Aug-2019
<b>Age/Sex</b>	49 Years/Female	<b>Specimen Type</b>	Tissue
<b>Patient ID</b>	011908020389	<b>Collection Date</b>	02-Aug-2019
<b>Specimen ID</b>	MOLQ/B-1482-19	<b>Report Date</b>	06-Aug-2019
<b>Client Name</b>	Lifeaid Wellness Centre, Gurgaon		

## SURGICAL PATHOLOGY REPORT

### Left Ovarian Cyst

#### DIAGNOSIS

### CYSTADENOMA



#### **SPECIMEN**

Left Ovarian Cyst

#### **GROSS**

Received 8x7 cm cyst already cut open, uniloculated cyst.

#### **Microscopy**

1. Section examined shows cuboidal lining epithelium with round to oval nucleus. Stroma shows fibrocollagenous tissue and blood vessels.
2. No granuloma seen. No malignant cells seen.

**Note :** All biopsy specimen will be stored for 15 (fifteen)days, block and slides for 5(five) years only from the time of receipt at the laboratory. No request ,for any of the above ,will be entertained after the due date.

#### **Reference**

- i) Rosai and Ackerman's Surgical Pathology.
- ii) Modern Surgical Pathology.

**Gulshan Yadav, MD**  
Consultant Pathologist