

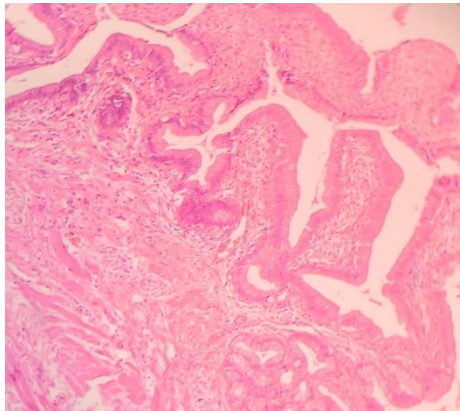
Patient Name	Mrs. KULSOOMA 10136	Specimen Received	05-Aug-2019
Age/Sex	65 Years/Female	Specimen Type	Tissue
Patient ID	011908010289	Collection Date	05-Aug-2019
Specimen ID	MOLQ/B-1482/19	Report Date	06-Aug-2019
	Client Name	Patients Care Clinical Laboratory, Jammu & Kashmir	

SURGICAL PATHOLOGY REPORT

GALL BLADDER.

DIAGNOSIS

CHOLECYSTITIS AND CHOLELITHIASIS.



SPECIMEN

Gall Bladder.

GROSS

Received 6.7x2.5 cm long gall bladder already cut open with stones.

Microscopy

- Section examined shows ulcerative mucosa and Rokitansky-Aschoff sinuses (irregularly shaped tubular structures lined by cuboidal lining epithelium with round to oval nucleus) with fibro collagenous tissue and inflammatory cells (lymphocytes).

Note : All biopsy specimen will be stored for 15 (fifteen) days, block and slides for 5 (five) years only from the time of receipt at the laboratory. No request ,for any of the above will be entertained after the due date.

Reference

- Rosai and Ackerman's Surgical Pathology.
- Modern Surgical Pathology.

Gulshan Yadav, MD
Consultant Pathologist