

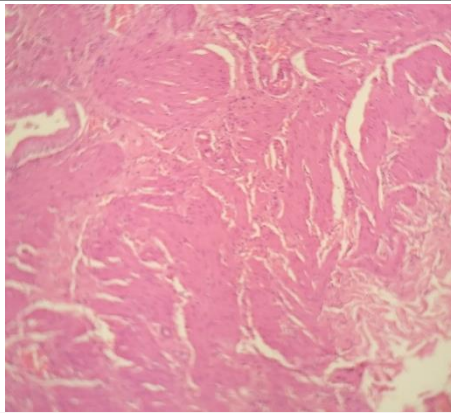
<b>Patient Name</b>	<b>Mrs. SHRIMATI DEVI</b>	<b>Specimen Received</b>	02-Aug-2019
<b>Age/Sex</b>	. Years/Female	<b>Specimen Type</b>	Tissue
<b>Patient ID</b>	011908020022	<b>Client Name</b>	Accurate Path (C), Agra
<b>Specimen ID</b>	MOLQ/B-1477/19	<b>Collection Date</b>	02-Aug-2019
		<b>Report Date</b>	05-Aug-2019

## SURGICAL PATHOLOGY REPORT

### GALL BLADDER.

#### DIAGNOSIS

#### CHOLECYSTITIS.



#### **SPECIMEN**

Gall Bladder.

#### **GROSS**

Received 9.9x4.4cm long gall bladder.

#### **Microscopy**

1. Section examined shows ulcerative mucosa and Rokitansky-Aschoff sinuses (irregularly shaped tubular structures lined by cuboidal lining epithelium with round to oval nucleus) with fibrocollagenous tissue and inflammatory cells (lymphocytes).

**Note :** All biopsy specimen will be stored for 15 (fifteen) days, block and slides for 5 (five) years only from the time of receipt at the laboratory. No request ,for any of the above will be entertained after the due date.

#### **Reference**

- i) Rosai and Ackerman's Surgical Pathology.
- ii) Modern Surgical Pathology.

**Gulshan Yadav, MD**  
Consultant Pathologist