

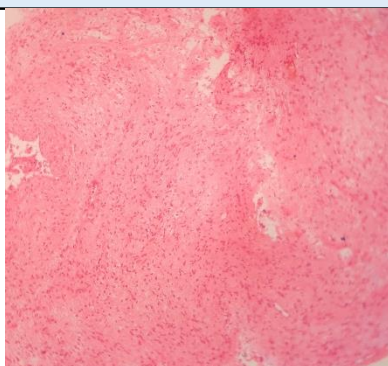
Patient Name	Mrs. MAMTA	Client Name	SRG Hospital, Kotla Vihar, Delhi	Specimen Received	05-Aug-2019
Age/Sex	40 Years/Female			Specimen Type	Tissue
Patient ID	011908010208			Collection Date	05-Aug-2019
Specimen ID	MOLQ/B-1476-19			Report Date	05-Aug-2019

SURGICAL PATHOLOGY REPORT

Endometrium

DIAGNOSIS

BLEEDING ENDOMETRIUM



SPECIMEN

Endometrium

GROSS

Received multiple grayish white tissue piece.

Microscopy

1. Paucicellular section examined shows occasional broken endometrial glands with cuboidal lining epithelium with small round nucleus and large number of RBCs.
2. No granuloma seen. No malignant cells seen.

Note : All biopsy specimen will be stored for 15 (fifteen)days, block and slides for 5(five) years only from the time of receipt at the laboratory. No request ,for any of the above ,will be entertained after the due date.

Reference

- i) Rosai and Ackerman's Surgical Pathology.
- ii) Modern Surgical Pathology.

Gulshan Yadav, MD
Consultant Pathologist