

Patient Name	Mrs. ANJU	Client Name:	Civil Hospital Sec-10, Gurgaon	Specimen Received	30-Jul-2019
Age/Sex	30 Years/Female			Specimen Type	Tissue
Patient ID	011907300383			Collection Date	30-Jul-2019
Specimen ID	MOLQ/B-1470-19			Report Date	05-Aug-2019

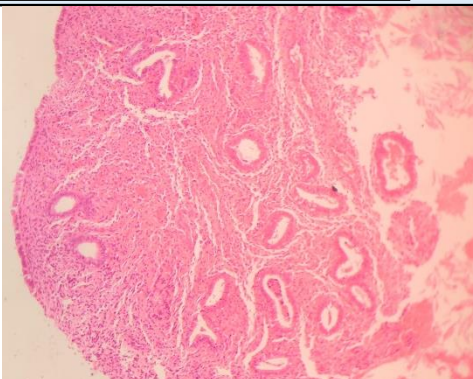
SURGICAL PATHOLOGY REPORT

? Endometrium Polyp

DIAGNOSIS

ENDOMETRIAL POLYP

KINDLY, CO-RELATE WITH RADIOLOGICAL FINDINGS.



SPECIMEN

? Endometrium Polyp

GROSS

Received multiple grayish white tissue piece.

Microscopy

1. Section examined shows mucosal lining epithelium and small endometrial glands with columnar lining with small round to oval nucleus and vacuolization. Stroma shows mononuclear inflammatory cells.
2. Ectocervix cells are also observed.
3. No granuloma seen. No malignant cells seen.

Note : All biopsy specimen will be stored for 15 (fifteen)days, block and slides for 5(five) years only from the time of receipt at the laboratory. No request ,for any of the above ,will be entertained after the due date.

Reference

- i) Rosai and Ackerman's Surgical Pathology.
- ii) Modern Surgical Pathology.

Gulshan Yadav, MD
Consultant Pathologist