

Patient Name Mrs. PARMEENA
Age/Sex 35 Years/Female
Patient ID 011907300155
Specimen ID MOLQ/B-1459-19

Client Name Global Diagnostic Center, Tauru

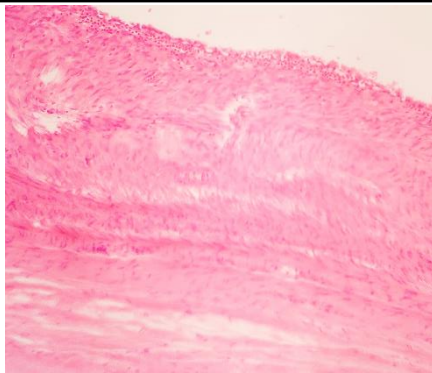
Specimen Received 30-Jul-2019
Specimen Type Tissue
Collection Date 30-Jul-2019
Report Date 05-Aug-2019

SURGICAL PATHOLOGY REPORT

Ovary and Tube

DIAGNOSIS

MUCINOUS CYSTADENOMA



SPECIMEN

Ovary and tube

GROSS

Received 12.6 X 11.9 cm ovary and tube. Cut section shows chocolate colored fluid also shows mucoid material.


Microscopy

1. Section examined shows multilayering of epithelium with round nucleus. Few cells shows atypia and anisonucleosis. Deeper tissue shows fibrocollagenous tissue and blood vessels.
2. Presence of mucoid material is also evident.

Note : All biopsy specimen will be stored for 15 (fifteen)days, block and slides for 5(five) years only from the time of receipt at the laboratory. No request ,for any of the above ,will be entertained after the due date.

Reference

- i) Rosai and Ackerman's Surgical Pathology.
- ii) Modern Surgical Pathology.



Gulshan Yadav, MD
Consultant Pathologist