

Patient Name Mr. AMIT
Age/Sex 27 Years/Male
Patient ID 011907280104
Specimen ID MOLQ/B-1452-19

Client Name: Polaris Hospital,
Gurgaon

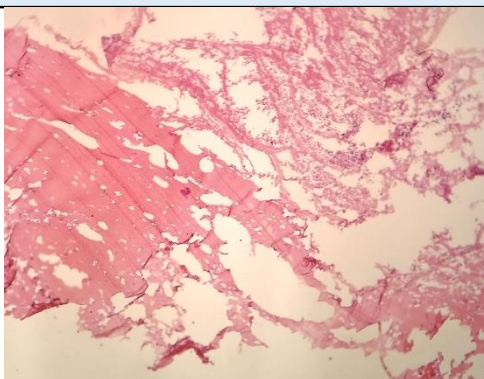
Specimen Received 28-Jul-2019
Specimen Type Tissue
Collection Date 28-Jul-2019
Report Date 02-Aug-2019

SURGICAL PATHOLOGY REPORT

Cyst from nasal base region

DIAGNOSIS

DERMOID CYST



SPECIMEN

Cyst from nasal base region

GROSS

Received 1x1 cm grayish white tissue piece.


Microscopy

1. Section examined shows squamous lining epithelium, keratin flakes, blood vessels and hair follicles.
2. No granuloma seen. No malignant cells seen.

Note : All biopsy specimen will be stored for 15 (fifteen)days, block and slides for 5(five) years only from the time of receipt at the laboratory. No request ,for any of the above ,will be entertained after the due date.

Reference

- i) Rosai and Ackerman's Surgical Pathology.
- ii) Modern Surgical Pathology.



Gulshan Yadav, MD
Consultant Pathologist