

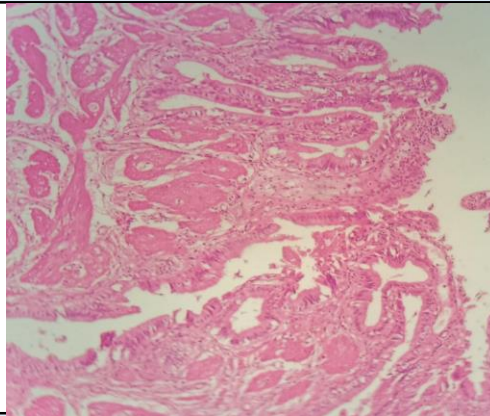
Patient Name	Mrs. MUSTAKEEM/PAMPORE	Client	A-One Collection Centre, Jammu & Kashmir	Specimen Received	28/07/2019
Age/Sex	40 Years/Female			Specimen Type	Tissue
Patient ID	041907270001			Collection Date	28/07/2019
Specimen ID	MOLQ/B-1450/19			Report Date	30/07/2019

SURGICAL PATHOLOGY REPORT

Gall Bladder

DIAGNOSIS

CHOLECYSTITIS AND CHOLELITHIASIS.



SPECIMEN

Gall Bladder

GROSS

Received 5.9x2cm long gall bladder. Cut section shows without stones.

Microscopy

Section examined shows ulcerative mucosa and Rokitansky-Aschoff sinuses (irregularly shaped tubular structures lined by cuboidal lining epithelium with round to oval nucleus) with fibro collagenous tissue and inflammatory cells (lymphocytes).

Note : All biopsy specimen will be stored for 15 (fifteen) days, block and slides for 5 (five) years only from the time of receipt at the laboratory. No request, for any of the above, will be entertained after the due date.

Reference

- i) Rosai and Ackerman's Surgical Pathology.
- ii) Modern Surgical Pathology.

Gulshan Yadav, MD
Consultant Pathologist