

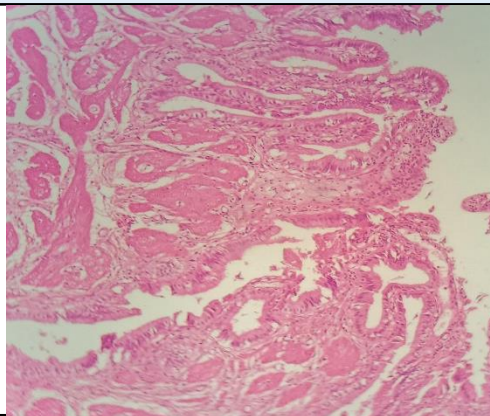
Patient Name	Mrs. MUSTAKEEM/PAMPORE	Client	A-One Collection Centre, Jammu & Kashmir	Specimen Received	28/07/2019
Age/Sex	40 Years/Female			Specimen Type	Tissue
Patient ID	041907270001			Collection Date	28/07/2019
Specimen ID	MOLQ/B-1450/19			Report Date	30/07/2019

SURGICAL PATHOLOGY REPORT

Gall Bladder

DIAGNOSIS

CHOLECYSTITIS.



SPECIMEN

Gall Bladder

GROSS

Received 5.9x2cm long gall bladder. Cut section shows without stones.

Microscopy

Section examined shows ulcerative mucosa and Rokitansky-Aschoff sinuses (irregularly shaped tubular structures lined by cuboidal lining epithelium with round to oval nucleus) with fibro collagenous tissue and inflammatory cells (lymphocytes).

Note : All biopsy specimen will be stored for 15 (fifteen) days, block and slides for 5 (five) years only from the time of receipt at the laboratory. No request, for any of the above, will be entertained after the due date.

Reference

- i) Rosai and Ackerman's Surgical Pathology.
- ii) Modern Surgical Pathology.

Gulshan Yadav, MD
Consultant Pathologist