

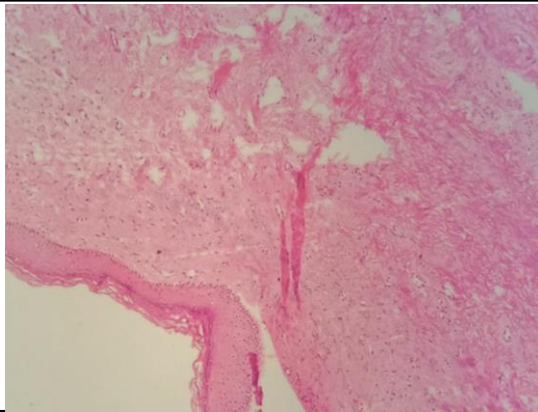
Patient Name	Mrs. BALA DEVI 35501	Client	Pushpanjali Hospital (Rewari)	Specimen Received	27/07/2019
Age/Sex	55 Years/Female			Specimen Type	Tissue
Patient ID	011907270274			Collection Date	27/07/2019
Specimen ID	MOLQ/B-1449/19			Report Date	30/07/2019

SURGICAL PATHOLOGY REPORT

vulvar

DIAGNOSIS

Skin tag.



SPECIMEN

vulvar

GROSS

Received tiny grayish white tissue piece.

Microscopy

Section examined shows squamous lining epithelium with mild hyperkeratosis small round nucleus, Deeper tissue shows fibro collagenous tissue, blood vessels, inflammatory cells. No granuloma and no malignant cells seen.

Note : All biopsy specimen will be stored for 15 (fifteen)days, block and slides for 5(five) years only from the time of receipt at the laboratory. No request ,for any of the above ,will be entertained after the due date.

Reference

- i) Rosai and Ackerman's Surgical Pathology.
- ii) Modern Surgical Pathology.

Gulshan Yadav, MD
Consultant Pathologist