

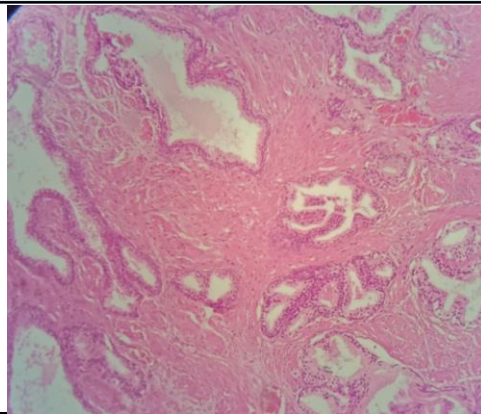
Patient Name	Mr. MURARI LAL 35463	Client	Pushpanjali Hospital (Rewari)	Specimen Received	27/07/2019
Age/Sex	65 Years/Male			Specimen Type	Tissue
Patient ID	011907270268			Collection Date	27/07/2019
Specimen ID	MOLQ/B-1446/19			Report Date	30/07/2019

SURGICAL PATHOLOGY REPORT

TURP Chips

DIAGNOSIS

BENIGN PROSTATIC HYPERPLASIA



SPECIMEN

TURP Chips

GROSS

Received multiple grayish white tissue piece, 2x3 cm in aggregate.

Microscopy

Section examined shows bilayered prostatic glands with columnar lining epithelium and with small round to oval nucleus surrounded by large number of fibrocollagenous tissue and mononuclear inflammatory cell.

No granuloma seen. No malignant cells seen.

Note : All biopsy specimen will be stored for 15 (fifteen)days, block and slides for 5(five) years only from the time of receipt at the laboratory. No request ,for any of the above ,will be entertained after the due date.

Reference

- i) Rosai and Ackerman's Surgical Pathology.
- ii) Modern Surgical Pathology.

Gulshan Yadav, MD
Consultant Pathologist