

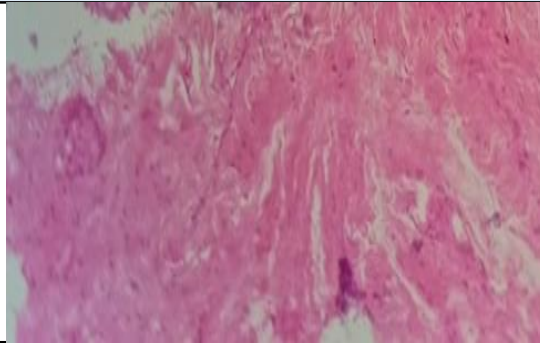
Patient Name	Mrs. BABITA	Client	Kriti Hospital	Specimen Received	27/07/2019
Age/Sex	32 YRS/F			Specimen Type	Tissue
Patient ID	011907270185			Collection Date	27/07/2019
Specimen ID	MOLQ/B-1444/19			Report Date	30/07/2019

SURGICAL PATHOLOGY REPORT

Endometrial biopsy

DIAGNOSIS

Disordered Proliferative Phase.



SPECIMEN

Endometrial biopsy

GROSS

Received multiple grayish white tissue piece.

Microscopy

Section examined shows small endometrial glands with cuboidal to columnar lining epithelium small round to oval nucleus with squamous metaplasia. Stroma shows mononuclear inflammatory cells section also shows fibrin and blood clot. No granuloma and no malignant cells seen

Note : All biopsy specimen will be stored for 15 (fifteen)days, block and slides for 5(five) years only from the time of receipt at the laboratory. No request ,for any of the above ,will be entertained after the due date.

Reference

- i) Rosai and Ackerman's Surgical Pathology.
- ii) Modern Surgical Pathology.

Gulshan Yadav, MD
Consultant Pathologist