

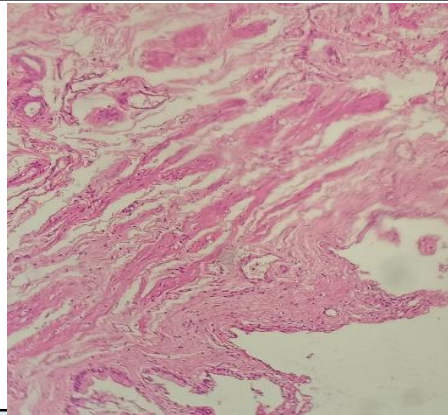
Patient Name NOWPORA	Mr. ASHIQ HUSSAIN 10058/Client	Patients Care Clinical Laboratory, Jammu & Kashmir	Specimen Received	26/07/2019
Age/Sex	. Years/Male		Specimen Type	Tissue
Patient ID	011907250394		Collection Date	26/07/2019
Specimen ID	MOLQ/B-1440/19		Report Date	30/07/2019

SURGICAL PATHOLOGY REPORT

Gall Bladder

DIAGNOSIS

CHOLECYSTITIS AND CHOLELITHIASIS.



SPECIMEN

Gall Bladder

GROSS

Received 8x3.2cm long gall bladder. Cut section shows stones.

Microscopy

- Section examined shows ulcerative mucosa and Rokitansky-Aschoff sinuses (irregularly shaped tubular structures lined by cuboidal lining epithelium with round to oval nucleus) with fibrocollagenous tissue and inflammatory cells (lymphocytes).

Note : All biopsy specimen will be stored for 15 (fifteen) days, block and slides for 5 (five) years only from the time of receipt at the laboratory. No request, for any of the above, will be entertained after the due date.

Reference

- Rosai and Ackerman's Surgical Pathology.
- Modern Surgical Pathology.

Gulshan Yadav, MD
Consultant Pathologist