

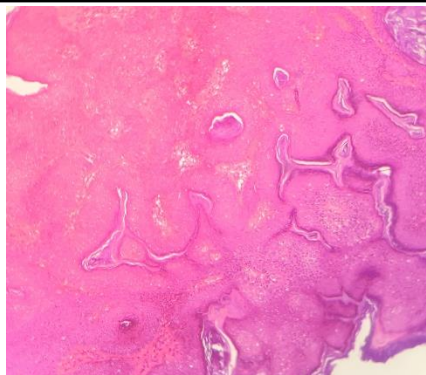
Patient Name	Mrs. PUSHPA	Client Name:	Civil Hospital Sec-10, Gurgaon	Specimen Received	24-Jul-2019
Age/Sex	60 Years/Female			Specimen Type	Tissue
Patient ID	011907240236			Collection Date	24-Jul-2019
Specimen ID	MOLQ/B-1419-19			Report Date	29-Jul-2019

SURGICAL PATHOLOGY REPORT

Skin Papilloma on Head

DIAGNOSIS

SQUAMOUS PAPILLOMA



SPECIMEN

Skin Papilloma on Head

GROSS

Received very tiny greyish white tissue piece.

Microscopy

1. Section examined shows squamous lining epithelium with round to oval nucleus, entrapping the fibrovascular core with hyperkeratosis and parakeratosis.
2. Few areas in the epithelium shows cells with pyknotic nucleus surrounded by clear halo suggestive of Koilocytes.
3. Fibrovascular core shows fibrocollagenous tissue and blood vessels.
4. No granuloma seen. No malignant cells seen.

Note : All biopsy specimen will be stored for 15 (fifteen)days, block and slides for 5(five) years only from the time of receipt at the laboratory. No request ,for any of the above ,will be entertained after the due date.

Reference

- i) Rosai and Ackerman's Surgical Pathology.
- ii) Modern Surgical Pathology.

Gulshan Yadav, MD
Consultant Pathologist