

<b>Patient Name</b>	<b>Ms. SAIMA /W/O:MOHD HUSAIN/ KAKPOORA</b>	<b>Client Name</b>	A-One Collection Centre, Jammu & Kashmir	<b>Specimen Received</b>	15-Jul-2019
<b>Age/Sex</b>	35 Years/Female			<b>Specimen Type</b>	Tissue
<b>Patient ID</b>	041907150032			<b>Collection Date</b>	26-Jul-2019
<b>Specimen ID</b>	MOLQ/B-1435-19			<b>Report Date</b>	28-Jul-2019

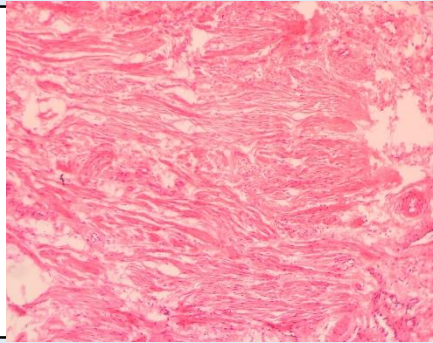
## SURGICAL PATHOLOGY REPORT

Intra muscle haemorrhagic cyst

### DIAGNOSIS

**Adenomyosis.**

**Kindly Co-relate clinically.**



#### SPECIMEN

Intra muscle haemorrhagic cyst

#### GROSS

Received multiple grayish white tissue piece.

#### Microscopy

1. Section examined shows muscle bundles with cystically dilated endometrial glands with cuboidal lining epithelium and small round nucleus.
2. No granuloma and no malignant cells seen.

**Note :** All biopsy specimen will be stored for 15 (fifteen)days, block and slides for 5(five) years only from the time of receipt at the laboratory. No request ,for any of the above ,will be entertained after the due date.

#### Reference

- i) Rosai and Ackerman's Surgical Pathology.
- ii) Modern Surgical Pathology.

**Gulshan Yadav, MD**  
Consultant Pathologist