

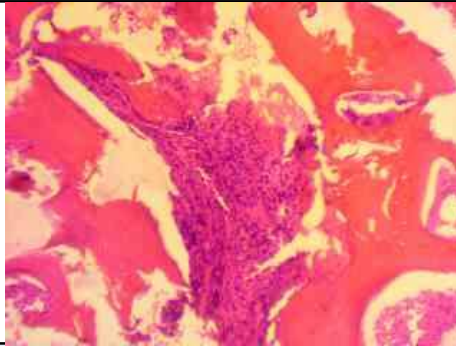
<b>Patient Name</b>	<b>Mr. RAM KUMAR</b>	<b>Client Name:</b>	Bharat Vikas Parishad,	<b>Specimen Received</b>	19-Jul-2019
<b>Age/Sex</b>	62 Years/Male		Gurgaon	<b>Specimen Type</b>	Tissue
<b>Patient ID</b>	021907190021			<b>Collection Date</b>	19-Jul-2019
<b>Specimen ID</b>	MOLQ/B-1383-19			<b>Report Date</b>	28-Jul-2019

## SURGICAL PATHOLOGY REPORT

### Bone Marrow Biopsy

#### DIAGNOSIS

**Few poorly preserved atypical cells seen.  
Advised for IHC marker studies to rule out metastatic malignancy.**



#### SPECIMEN

Bone Marrow Biopsy

#### GROSS

Received multiple grayish white tissue piece measuring 0.8x0.1 cm each.

#### Microscopy

1. Sections show bony trabeculae and marrow cavity.
2. Few atypical cells with poorly preserved morphology are seen ? malignant.

**Note :** All biopsy specimen will be stored for 15 (fifteen)days, block and slides for 5(five) years only from the time of receipt at the laboratory. No request ,for any of the above ,will be entertained after the due date.

#### Reference

- i) Rosai and Ackerman's Surgical Pathology.
- ii) Modern Surgical Pathology.

**Gulshan Yadav, MD  
Consultant Pathologist**