

Patient Name Mr. SHURYA
Age/Sex 19 Years/Male
Patient ID 011907250011
Specimen ID MOLQ/B-1428-19

Client Name Umkal Hospital
Gurgaon

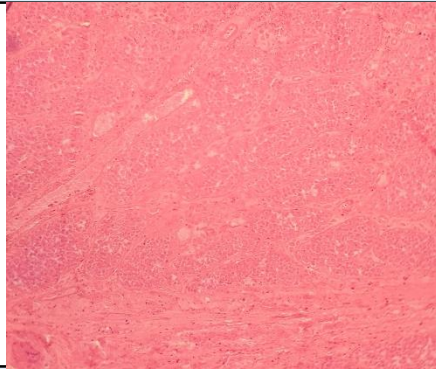
Specimen Received 25-Jul-2019
Specimen Type Tissue
Collection Date 25-Jul-2019
Report Date 28-Jul-2019

SURGICAL PATHOLOGY REPORT

Testis

DIAGNOSIS

Hemorrhagic and necrotic testis
(Due to torsion)



SPECIMEN

Testis

GROSS

Received 3.2x5 cm long testes with epididymis cut section shows blood clot.

Microscopy

1. Section examined shows seminiferous tubules with necrosis and degeneration surrounded by degenerating supporting cells and blood vessels.
2. No granuloma and no malignant cells seen.

Note : All biopsy specimen will be stored for 15 (fifteen)days, block and slides for 5(five) years only from the time of receipt at the laboratory. No request ,for any of the above ,will be entertained after the due date.

Reference

- i) Rosai and Ackerman's Surgical Pathology.
- ii) Modern Surgical Pathology.



Gulshan Yadav, MD
Consultant Pathologist