

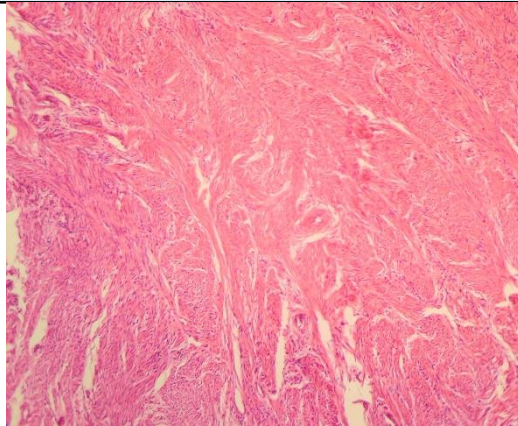
<b>Patient Name</b>	<b>Mrs. RAJO</b>	<b>Client Name</b>	Civil Hospital Sec-10, Gurgaon	<b>Specimen Received</b>	22-Jul-2019
<b>Age/Sex</b>	40 Years/Female			<b>Specimen Type</b>	Tissue
<b>Patient ID</b>	011907220127			<b>Collection Date 2</b>	22-Jul-2019
<b>Specimen ID</b>	MOLQ/B-1405/19			<b>Report Date</b>	28-Jul-2019

## SURGICAL PATHOLOGY REPORT

Uterus with Cervix

### DIAGNOSIS

### CHRONIC CERVICITIS



#### SPECIMEN

Uterus with Cervix

#### GROSS

Received 10x7cm uterus with cervix with bilateral adnexa. Ovary size 2x2 cm, 3x2 cm cut section shows blood clot cyst size 1x2cm.

#### Microscopy

Section examined shows

- 1)Endometrium with proliferative phase
- 2)Myometrium with superficial adenomyosis
- 3)Cervix with mononuclear inflammatory cells
- 4)Ovary and tube unremarkable
- 5)Other ovary with Hemorrhagic and tube unremarkable

**Note :** All biopsy specimen will be stored for 15 (fifteen)days, block and slides for 5(five) years only from the time of receipt at the laboratory. No request ,for any of the above ,will be entertained after the due date.

#### Reference

- i) Rosai and Ackerman's Surgical Pathology.
- ii) Modern Surgical Pathology.

**Gulshan Yadav, MD**  
Consultant Pathologist