

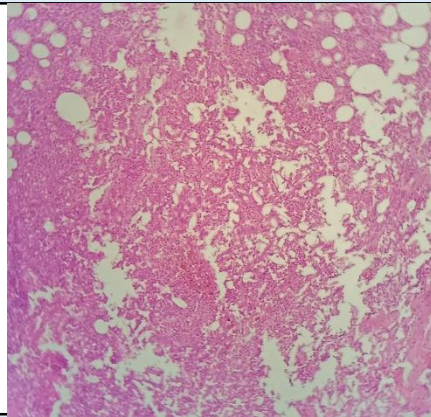
Patient Name	Mr. PARMESH	Client	Tanisha Clinical Laboratory	Specimen Received	20/07/2019
Age/Sex	27 Years/Male			Specimen Type	Tissue
Patient ID	011907200211			Collection Date	20/07/2019
Specimen ID	MOLQ/B-1389/19			Report Date	27/07/2019

SURGICAL PATHOLOGY REPORT

Posterior upper lumber resion chest.

DIAGNOSIS

Foreign body type of granuloma with granulation tissue.



SPECIMEN

Posterior upper lumber resion chest.

GROSS

Received two grayish white tissue piece measuring 2.8x1.6,1x1cm

Microscopy

- Section examined shows squamous lining epithelium with round nucleus and fibro collagenous tissue with lymphocytes, multinucleated giant cells, polymorphs and mature adipose cells. Presence of normal glands hair follicle. No granuloma and malignant cells seen .

Note : All biopsy specimen will be stored for 15 (fifteen)days, block and slides for 5(five) years only from the time of receipt at the laboratory. No request ,for any of the above ,will be entertained after the due date.

Reference

- Rosai and Ackerman's Surgical Pathology.
- Modern Surgical Pathology.

**Gulshan Yadav, MD
Consultant Pathologist**