

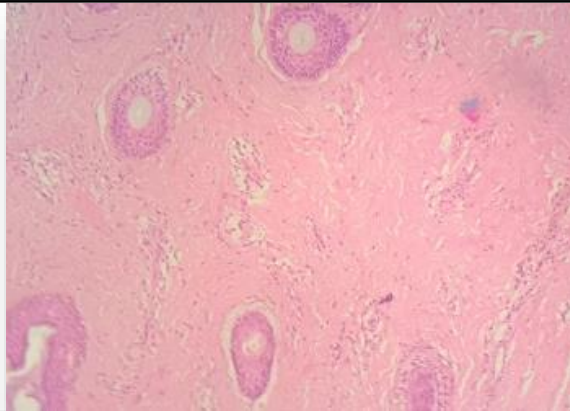
| | | | | | |
|---------------------|--------------------------|---------------|---|--------------------------|------------|
| Patient Name | Mr. INTIKHAB ALAM | Client | Patients Care Clinical Laboratory, Jammu & Kashmir | Specimen Received | 19/07/2019 |
| Age/Sex | Years/Male | | | Specimen Type | Tissue |
| Patient ID | 011907190308 | | | Collection Date | 19/07/2019 |
| Specimen ID | MOLQ/B-1379/19 | | | Report Date | 27/07/2019 |

SURGICAL PATHOLOGY REPORT

Interior gall bladder cyst.

DIAGNOSIS

Benign cystic lesion with inflammation



SPECIMEN

Interior gall bladder cyst.

GROSS

Received 4x3cm grayish white tissue piece cut section shows calcified tissue.

Microscopy

1. Section examined shows autolyzed lining epithelium ,fibro collagenous tissue mature adipose cells few inflammatory cells(Lymphocytes, plasma cells).

No granuloma and no malignant cells seen.

Note : All biopsy specimen will be stored for 15 (fifteen)days, block and slides for 5(five) years only from the time of receipt at the laboratory. No request ,for any of the above ,will be entertained after the due date.

Reference

- i) Rosai and Ackerman's Surgical Pathology.
- ii) Modern Surgical Pathology.

**Gulshan Yadav, MD
Consultant Pathologist**