

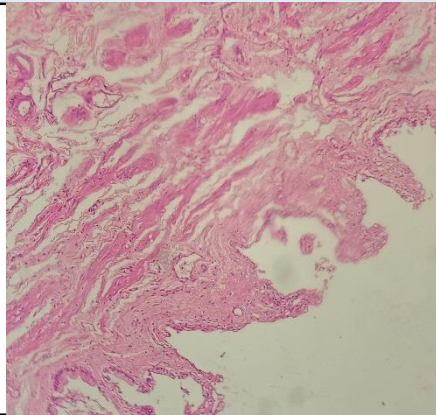
Patient Name	Mrs. MAROOF/WATRAGAN	Client Name	Patients Care Clinical Laboratory, Jammu & Kashmir	Specimen Received	22/07/19
Age/Sex	33 YRS/F			Specimen Type	Tissue
Patient ID	011907220061			Collection Date	22/07/19
Specimen ID	MOLQ/B-1403/19			Report Date	26/07/19

SURGICAL PATHOLOGY REPORT

Gall bladder

DIAGNOSIS

CHOLECYSTITIS AND CHOLELITHIASIS.



SPECIMEN

Gall bladder

GROSS

Received 7x3cm long gall bladder. Cut section shows tiny stones.

Microscopy

Section examined shows autolytic changes with ulcerative mucosa and rokitansky aschoff sinus (irregularly shaped tubular structures lined by cuboidal lining epithelium with round to oval nucleus) with fibro collagenous tissue and inflammatory cells (lymphocytes).

Note : All biopsy specimen will be stored for 15 (fifteen)days, block and slides for 5(five) years only from the time of receipt at the laboratory. No request ,for any of the above ,will be entertained after the due date.

Reference

- i) Rosai and Ackerman's Surgical Pathology.
- ii) Modern Surgical Pathology.

Gulshan Yadav, MD
Consultant Pathologist