

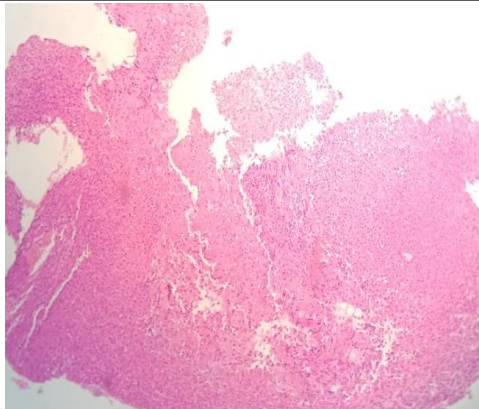
<b>Patient Name</b>	<b>Mr. SHISHPAL-35006</b>	<b>Client</b>	Pushpanjali Hospital (Rewari)	<b>Specimen Received</b>	21/07/2019
<b>Age/Sex</b>	48 Years/Male			<b>Specimen Type</b>	Tissue
<b>Patient ID</b>	011907210137			<b>Collection Date</b>	21/07/2019
<b>Specimen ID</b>	MOLQ/B-1396/19			<b>Report Date</b>	26/07/2019

## SURGICAL PATHOLOGY REPORT

Endoscopic biopsy

### DIAGNOSIS

**Non specific inflammation.**  
**Kindly Co- relate clinically**



#### SPECIMEN

Endoscopic biopsy

#### GROSS

Received multiple grayish white tissue piece.

#### Microscopy

- Section examined shows mucosal lining epithelium with round to oval nucleus. Submucosa shows glands with columnar lining epithelium surrounding by mononuclear inflammatory cells. No granuloma and no malignant cells seen in sample received.

**Note :** All biopsy specimen will be stored for 15 (fifteen)days, block and slides for 5(five) years only from the time of receipt at the laboratory. No request ,for any of the above ,will be entertained after the due date.

#### Reference

- Rosai and Ackerman's Surgical Pathology.
- Modern Surgical Pathology.

**Gulshan Yadav, MD**  
**Consultant Pathologist**