

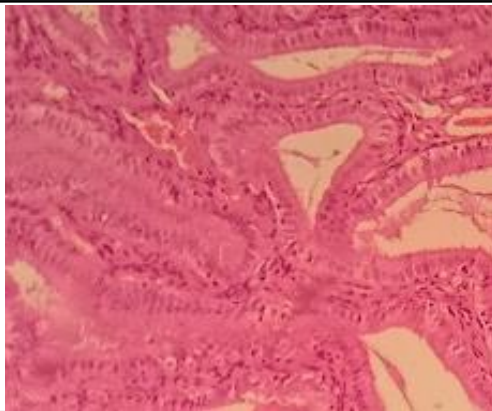
Patient Name	Mr. TAHIRA RASHID/LG	Client	Patients Care Clinical Laboratory, Jammu & Kashmir	Specimen Received	21/07/2019
PORA				Specimen Type	Tissue
Age/Sex	Years/Male			Collection Date	21/07/2019
Patient ID	011907210135			Report Date	26/07/2019
Specimen ID	MOLQ/B-1401/19				

SURGICAL PATHOLOGY REPORT

Gall Bladder

DIAGNOSIS

CHOLECYSTITIS AND CHOLELITHIASIS.



SPECIMEN

Gall Bladder

GROSS

Received 5.6x2.8cm long gall bladder. Cut section shows stones.

Microscopy

- Section examined shows ulcerative mucosa and rokitansky aschoff sinus (irregularly shaped tubular structures lined by cuboidal lining epithelium with round to oval nucleus) with fibro collagenous tissue and inflammatory cells (lymphocytes).

Note : All biopsy specimen will be stored for 15 (fifteen)days, block and slides for 5(five) years only from the time of receipt at the laboratory. No request ,for any of the above ,will be entertained after the due date.

Reference

- Rosai and Ackerman's Surgical Pathology.
- Modern Surgical Pathology.

Gulshan Yadav, MD
Consultant Pathologist