

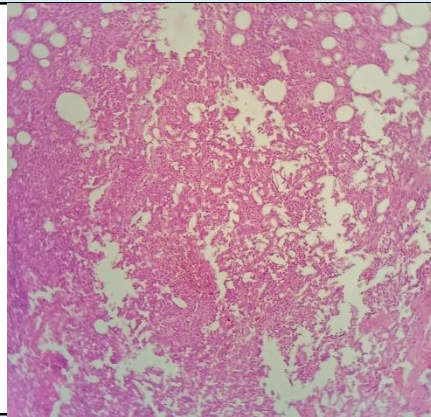
<b>Patient Name</b>	<b>Mr. PARMESH</b>	<b>Client</b>	Tanisha Clinical Laboratory	<b>Specimen Received</b>	20/07/2019
<b>Age/Sex</b>	27 Years/Male			<b>Specimen Type</b>	Tissue
<b>Patient ID</b>	011907200211			<b>Collection Date</b>	20/07/2019
<b>Specimen ID</b>	MOLQ/B-1389/19			<b>Report Date</b>	26/07/2019

## SURGICAL PATHOLOGY REPORT

Posterior upper lumbar resion chest.

### DIAGNOSIS

**Foreign body type of granuloma reaction with inflammation.**



#### SPECIMEN

Posterior upper lumbar resion chest.

#### GROSS

Received two grayish white tissue piece measuring 2.8x1.6,1x1cm

#### Microscopy

- Section examined shows squamous lining epithelium with round nucleus and fibro collagenous tissue with lymphocytes, multinucleated giant cells, polymorphs and mature adipose cells. Presence of normal glands hair follicle. No granuloma and malignant cells seen .

**Note :** All biopsy specimen will be stored for 15 (fifteen)days, block and slides for 5(five) years only from the time of receipt at the laboratory. No request ,for any of the above ,will be entertained after the due date.

#### Reference

- Rosai and Ackerman's Surgical Pathology.
- Modern Surgical Pathology.

**Gulshan Yadav, MD  
Consultant Pathologist**