

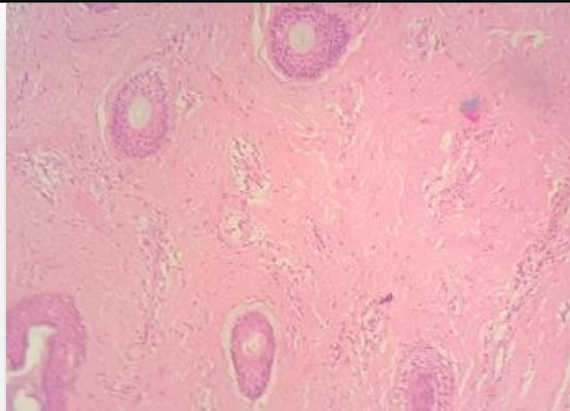
Patient Name	Mr. INTIKHAB ALAM	Client	Patients Care Clinical Laboratory, Jammu & Kashmir	Specimen Received	19/07/2019
Age/Sex	Years/Male			Specimen Type	Tissue
Patient ID	011907190308			Collection Date	19/07/2019
Specimen ID	MOLQ/B-1379/19			Report Date	26/07/2019

SURGICAL PATHOLOGY REPORT

Interior gall bladder cyst.

DIAGNOSIS

Benign cystic lesion.



SPECIMEN

Interior gall bladder cyst.

GROSS

Received 4x3cm grayish white tissue piece cut section shows calcified tissue.

Microscopy

1. Section examined shows autolyzed lining epithelium ,fibro collagenous tissue mature adipose cells few inflammatory cells9Lymphocytes, plasma cells.

No granuloma and no malignant cells seen.

Note : All biopsy specimen will be stored for 15 (fifteen)days, block and slides for 5(five) years only from the time of receipt at the laboratory. No request ,for any of the above ,will be entertained after the due date.

Reference

- i) Rosai and Ackerman's Surgical Pathology.
- ii) Modern Surgical Pathology.

**Gulshan Yadav, MD
Consultant Pathologist**