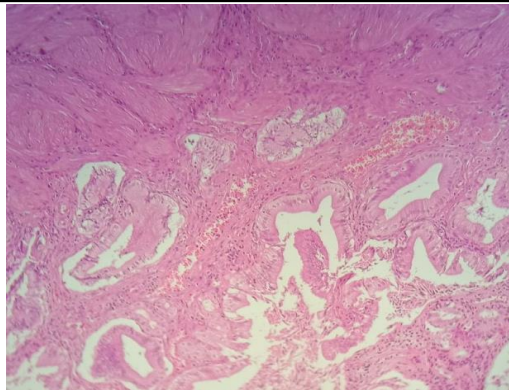


Patient Name	Mrs. KAMLESH	Client	MolQ Collection Centre CSK	Specimen Received	21/07/19
Age/Sex	55 Years/Female	Hospita, Sohna		Specimen Type	Tissue
Patient ID	011907210207			Collection Date	21/07/19
Specimen ID	MOLQ/B-1397/19			Report Date	25/07/19

SURGICAL PATHOLOGY REPORT Gall Bladder

DIAGNOSIS

CHOLECYSTITIS AND CHOLELITHIASIS.



SPECIMEN

Gall Bladder

GROSS

Received 7.4x3.4cm long gall bladder. Cut section shows stones wall thickened.

Microscopy

Section examined shows ulcerative mucosa and Rokitansky-Aschoff sinus (irregularly shaped tubular structures lined by cuboidal lining epithelium with round to oval nucleus) with fibrocollagenous tissue and inflammatory cells (lymphocytes).

Note : All biopsy specimen will be stored for 15 (fifteen) days, block and slides for 5 (five) years only from the time of receipt at the laboratory. No request, for any of the above, will be entertained after the due date.

Reference

- i) Rosai and Ackerman's Surgical Pathology.
- ii) Modern Surgical Pathology.

Gulshan Yadav, MD
Consultant Pathologist