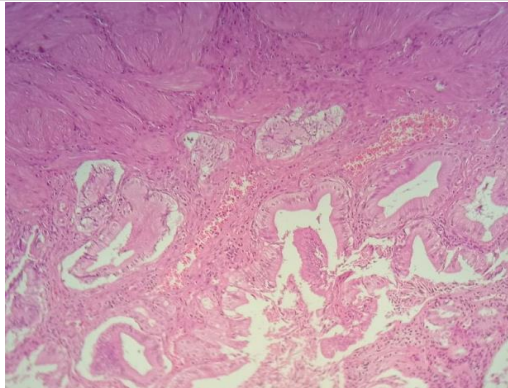


<b>Patient Name</b>	<b>Mrs. OMWATI</b>	<b>Client</b>	Kriti Hospital	<b>Specimen Received</b>	21/07/19
<b>Age/Sex</b>	50 Years/Female			<b>Specimen Type</b>	Tissue
<b>Patient ID</b>	011907210153			<b>Collection Date</b>	21/07/19
<b>Specimen ID</b>	MOLQ/B-1395/19			<b>Report Date</b>	25/07/19

## SURGICAL PATHOLOGY REPORT Gall Bladder

### DIAGNOSIS

### CHOLECYSTITIS AND CHOLELITHIASIS.



#### SPECIMEN

Gall Bladder

#### GROSS

Received 5.9x2.8cm long gall bladder. Cut section shows stones and wall thickened 0.2cm.

#### Microscopy

Section examined shows ulcerative mucosa and Rokitansky-Aschoff sinuses (irregularly shaped tubular structures lined by cuboidal lining epithelium with round to oval nucleus) with fibro collagenous tissue and inflammatory cells (lymphocytes).

**Note :** All biopsy specimen will be stored for 15 (fifteen) days, block and slides for 5 (five) years only from the time of receipt at the laboratory. No request, for any of the above, will be entertained after the due date.

#### Reference

- i) Rosai and Ackerman's Surgical Pathology.
- ii) Modern Surgical Pathology.



**Gulshan Yadav, MD**  
Consultant Pathologist