

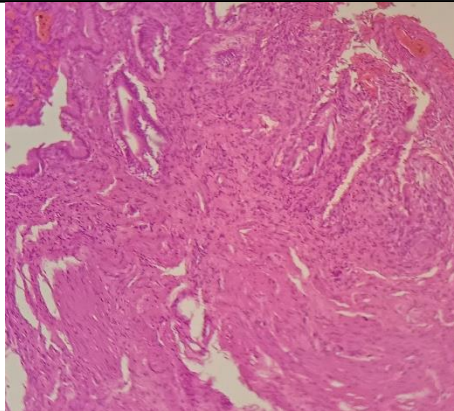
Patient Name Mrs. AFROOZA 3478 VILLAGAM CHOWK	Client Apollo Laboratories CC, Jammu & Kashmir	Specimen Received 18/07/2019
Age/Sex 32 Years/Female	Ref. Doctor DR S M MAQBOOL MS	Specimen Type Tissue
Patient ID 011907160265		Collection Date 18/07/2019
Specimen ID MOLQ/B-1350/19		Report Date 24/07/2019

SURGICAL PATHOLOGY REPORT

Gall bladder

DIAGNOSIS

CHOLECYSTITIS WITH CHOLELITHIASIS



SPECIMEN

Gall bladder

GROSS

Received 6x3.2cm long gall bladder cut section shows stones.

Microscopy

- Section examined shows ulcerative mucosa and rokitansky aschoff sinus (irregularly shaped tubular structures lined by cuboidal lining epithelium with round to oval nucleus) with fibro collagenous tissue and inflammatory cells (lymphocytes).

Note : All biopsy specimen will be stored for 15 (fifteen)days, block and slides for 5(five) years only from the time of receipt at the laboratory. No request ,for any of the above ,will be entertained after the due date.

Reference

- Rosai and Ackerman's Surgical Pathology.
- Modern Surgical Pathology.

**Gulshan Yadav, MD
Consultant Pathologist**